

## CHAPTER 6

### URINARY INCONTINENCE POST-FISTULA REPAIR

Section 6.1: Causes and evaluation of post-repair incontinence
Section 6.2: Conservative treatment of post-repair incontinence
Section 6.3: Surgery for stress incontinence: general
Section 6.4: Surgery for stress incontinence: repairing defects in the fascia
Section 6.5: Surgery for stress incontinence: sling operations and other options
Section 6.6: Urethral stricture

#### (6.1) CAUSES AND EVALUATION OF POST-REPAIR INCONTINENCE

At least a quarter of women whose fistulas have been closed successfully remain incontinent and these patients are classified as having post-repair incontinence. It seems the longer the follow up, the higher the incidence becomes. Causes include stress incontinence, detrusor over-activity and voiding dysfunction. The patient can leak as much trans-urethrally after surgery as she did through the original fistula. *Reference: Urinary incontinence following obstetric fistula repair: World J Obstet Gynecol 2016 May 10; 5(2): 182-186. Goh J.*

- (a) The most important factor in post-repair incontinence is the extent of any urethral damage. There is loss of the bladder neck/ posterior urethra and the overlying pubo-cervical fascia. This results in loss of coaptation of the anterior/ posterior urethra rather than urethral hyper-mobility.
- The posterior urethra may lack the normal support of the pubo-cervical fascia and the vaginal wall.
  - The anterior urethra is often fixed to the back of the pubic symphysis, especially with circumferential defects. This interferes with the normal mobility of the urethra which is important in continence.
- (b) Reduced bladder capacity due to bladder damage with a large fistula is a less common cause.

SUMMARY OF POST-REPAIR URINARY INCONTINENCE		
TYPE	DIAGNOSIS	TREATMENT
<b>Stress</b>	<p><i>Hx:</i> The patient is usually dry in bed and wet on standing or with activity or with cough.</p> <p><i>Ex:</i> Look for leakage of urine via the urethra on coughing. To ensure that it is pure stress, exclude:</p> <ul style="list-style-type: none"> <li>• A small fistula close to the urethra: even if urine is passed through the urethra.</li> <li>• Bladder stone or small bladder capacity.</li> <li>• Overflow: measure residual volume.</li> </ul>	<p><i>Conservative:</i> wait 4-6 months. Pelvic floor exercises may help but are unlikely to cure incontinence.</p> <p style="text-align: center;">(Urethral plugs if available.)</p> <p><i>Surgery:</i> Either or both: (a) Repair of the endopelvic fascia (b) Fascial sling.</p>
<b>Urgency</b>	<p><i>Hx:</i> Ask about frequency and urgency. If nocturia exceeds two times per night, this suggests urgency. If she is not getting up at night, this indicates a good bladder capacity and no urgency.</p> <p><i>Ex:</i> Check for a small bladder capacity/ cystometry. With a metal catheter, check for bladder stones which are not uncommon after a fistula repair especially if the patient still has some incontinence.</p> <p><i>Investigation:</i> Exclude a urinary tract infection. Ask her to keep a voiding diary to see bladder capacity.</p>	<ul style="list-style-type: none"> <li>• Pelvic floor exercises.</li> <li>• Anti-cholinergic e.g. Oxybutynin 5 to 15 mg/ day.</li> <li>• Bladder drill: drink plenty and timed voiding.</li> <li>• Bladder augmentation to increase capacity.</li> <li>• Bladder Botox and neuromodulation.</li> </ul>
<b>Overflow: stricture or bladder atony</b>	<p><i>Hx:</i> Usually the patient is wet in the bed as well as with standing. She may have difficulty passing urine.</p> <p><i>Ex:</i> The urine comes through the urethra especially when she coughs and so it may be misdiagnosed as “stress”. Measure the residual urine after voiding.</p>	<ul style="list-style-type: none"> <li>• Intermittent self-catheterisation.</li> <li>• Timed voiding and double voiding.</li> <li>• If stricture: dilation or urethroplasty.</li> </ul>
<b>Fistula</b>	<ul style="list-style-type: none"> <li>• <i>Bladder:</i> Do dye test to exclude bladder fistula.</li> <li>• <i>Ureteric:</i> Do ultrasound of kidneys if you suspect a ureteric fistula to look for hydronephrosis.</li> </ul>	<ul style="list-style-type: none"> <li>• <i>Conservative:</i> Catheter treatment if VVF discovered early enough.</li> <li>• <i>Surgery.</i></li> </ul>
<b>Mixed</b>	Stress and urgency is the most common combination.	May treat the stress first as this restores normal bladder filling and emptying.

In one study, 50% of those who leaked on walking after repair were dry at six months. *Reference: Women with obstetric fistula in Ethiopia: a 6-month follow-up after surgical treatment: Browning A, Menber B. BJOG. 2008*

Nov; 115(12):1564. However, the opposite often happens. The patient may go home “dry” only to return later with severe stress incontinence.

**Incontinence persisting after repair can be predicted by:**

(1) *Urethral involvement*: this is the strongest determining risk factor with the risk of persistent incontinence being 8.4 times greater.

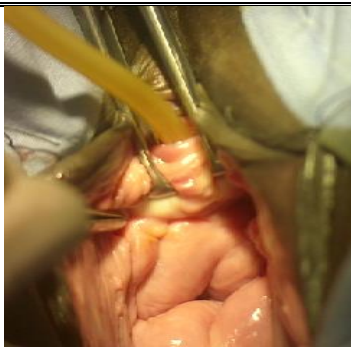

- The urethra is involved in up to two-thirds of fistulas.
- The shorter the distance from the external urethral opening to the fistula, the more likely stress incontinence is to occur post-operatively. The critical urethral length for continence is approximately 1.5 to 2 cm. Those with Goh or Waaldijk Type 1 fistula are most likely to be continent whereas those with Goh Type 4 or Waaldijk Type 2Bb are least likely to be continent.
- The normal female urethra is about 4 cm long. The average length of the urethra in patients with stress incontinence post-repair is 1.4 cm.

(2) *Size of the original defect*: The risk for persistent incontinence increases by 1.34 times for each 1 cm increase in the diameter of the defect.

(3) *Significant vaginal scarring*: i.e. scarring that is severe enough to prevent the use of a Sims speculum without incising it. The risk for persistent incontinence is 2.4 times greater.

(4) *Small bladder capacity*: The risk for persistent incontinence is 4.2 times greater. A small bladder capacity in this study means the bladder is unable to contain 100 ml of fluid at the end of surgery.

*Reference: Browning A. Risk factors for developing residual urinary incontinence after obstetric fistula repair. BJOG 2006; 113:482-485.* In this study circumferential involvement, a very important risk factor for developing stress incontinence, was not analyzed separately.

	<p><i>Fig. 6.1a: When doing a dye test in cases of post-repair incontinence, to prevent the dye leaking out through the urethra, an Allis forceps is placed on either side of the urethra as shown. Then as you inject the dye, distal traction on the Allis forceps is applied to prevent leakage through the urethra. If the patient is not anaesthetized, you can compress the urethra with a swab.</i></p>	<p><b>For any patient with post-repair incontinence:</b></p> <div style="text-align: right; margin-bottom: 10px;">  </div> <ul style="list-style-type: none"> <li>➤ Do a dye test as this often reveals a small fistula.</li> <li>➤ Exclude any bladder stones.</li> <li>➤ Check bladder size, capacity and pressures.</li> </ul>
--	--	---

**EVALUATING A PATIENT WITH POST-REPAIR INCONTINENCE**

The key to managing these patients is to make an accurate diagnosis. So take a good history, examine them carefully with a good light, speculum and do a dye test. It helps if the patient has a full bladder so have her drink plenty of fluids prior to examination.

(1) **Estimate urethral function:**

- Although it is difficult to be sure if the urethra is intact, a length of 3 cm or more should be adequate provided scarring is minimal. (See Fig. 1.6 a + b on how to measure urethral length.)
- A urethral plug (Appendix 8) may also be tried because if the patient is dry with this, the problem is clearly urethral rather than bladder related. However, if she is wet with the plug, this does not exclude a urethral cause. Also, even if you think there is a small bladder, the capacity may increase with the use of a plug.

(2) **Estimate total bladder size:** The length from the external urethral opening (EUO) to the dome of the bladder (DOB) is measured with a sound.

*Normal:* should be  $\geq 8$  cm and if it is, it suggests the problem is stress incontinence rather than a bladder problem and usually requires alternative treatment e.g. stress operation or plug.

*Abnormal:* a length of  $\leq 6$  cm, suggests a small bladder capacity. These patients are nearly always wet secondary to small capacity.

*Borderline:* 7 cm is a borderline measurement and other causes should be excluded.

Note: You can measure the true bladder length by measurement of total bladder length minus the urethral length. A true bladder length of  $< 6$  cm is small.

(3) **Estimate bladder capacity  $\pm$  pressures:**

- Insert a Foley catheter into the bladder after voiding and measure the residual volume to exclude urinary retention as a cause of overflow incontinence.
- *Gravity dye test:* Attach a bladder syringe without the plunger to the Foley catheter held about 20 cm above the external urethral orifice and pour the fluid into this. You can pinch the Foley catheter as you

fill the syringe so that you know how much you have poured in. The bladder is filled by gravity with 50 ml, then 100 ml of water or saline. (If there is leakage before 100 ml, press on the urethra to occlude it or pull on the Foley catheter so that the balloon occludes the urethra.) Filling may be stopped at 150 ml (normal bladder capacity is 350 to 400 ml). If 100-150 ml flows into the bladder, this suggests that the bladder capacity is okay. If there is no marked urge to urinate by the time 150 ml is inserted, then the catheter is removed and the patient is assessed for stress incontinence.

- *Bladder diary*: Ask the patient to measure and record the volume of urine she voids for a period of 3 days. Analyse the average volume she passes (functional capacity) and night frequency (nocturia).

**!Tip!** When doing the dye test, it is easy to miss a pinhole fistula of the urethra as the Foley catheter may be against the fistula. It helps to move the catheter once the dye is injected to allow dye to leak out through any fistula.

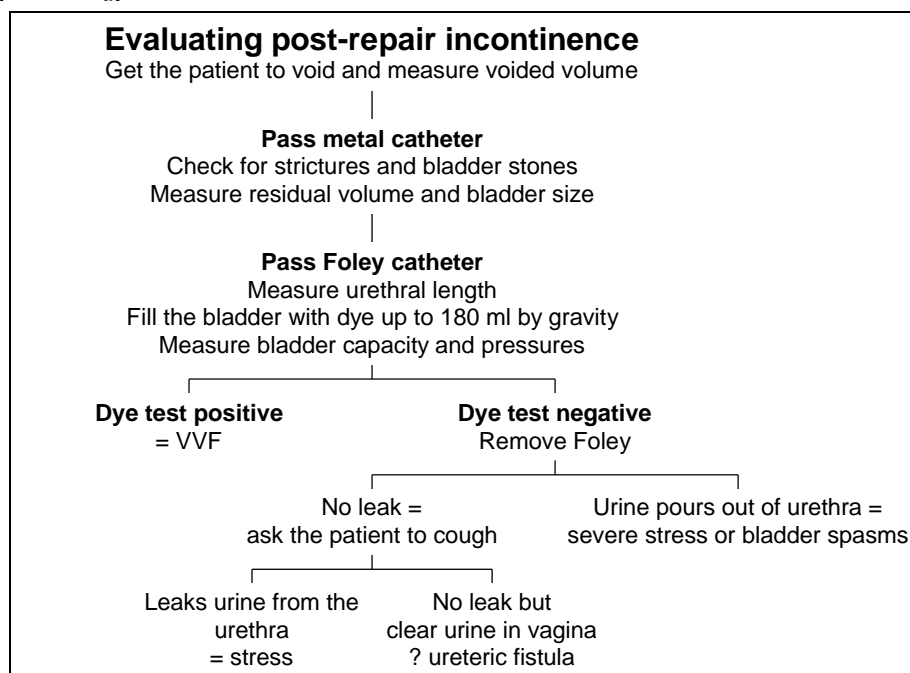
- *Bladder pressures*: This can be estimated by observing the fluid level in the syringe or the Foley catheter as in Fig. 1.24 g + h. If this is less than 20 cm i.e. above the meatus with the bladder holding at least 100 ml of water, then significant urge incontinence is excluded and stress incontinence is suspected.
  - Changes in the intra-vesical pressure are apparent as fluctuations in the fluid level i.e. the meniscus in the syringe.
  - Ask the patient if she feels her bladder is full at any time. Any sudden rise in pressure accompanied by an urge to void indicates an involuntary bladder contraction and detrusor instability, although increases in abdominal pressure can masquerade as bladder spasms.

**!Tip!** During cystometry, you have to remember that any pressure changes seen are changes in bladder pressure, not necessarily bladder contractions. Any increase in intra-abdominal pressure (movement, cough, strain, even talking) will lead to fluctuations in intra-abdominal/ bladder pressure. The combination of symptoms with pressure change is much more clinically valid than pressure change alone.

#### (4) Evaluate vaginal elasticity and mobility:

- Patients often leak when pressure is exerted with a speculum on the posterior vaginal wall. This is thought to be due to stretching of the vagina removing any remaining elasticity which is already deficient. Such patients may require a skin flap (see page 90 and chapter 8) to restore the normal elasticity. This has been found to reduce the risk of stress incontinence.
- If there is little mobility of the anterior vagina, then a sling is less likely to work.

*Reference: Browning A, Williams G, Petros P, Prevention and cure of post vesico-vaginal fistula repair incontinence by insertion of skin graft in the bladder neck area of vagina- update on hypothesis and interim report; Pelviperineology 2017; 36: 9-11.*



**Case History:** The following is included to show how difficult it can be to make a diagnosis of what is causing “post-repair incontinence”. A 30-year-old patient had four previous repairs and now has “post-repair

incontinence". She was wet more during the day than during the night. During the last repair, the bladder capacity was recorded as 40 ml.

- *In the outpatient clinic:* It was uncertain if the problem was due to a small bladder or an incompetent urethra. When bedside cystometry was performed, the bladder pressures appeared high. The dye test was negative but dye poured out through the urethra.
- *In the operating room:* A gravity dye test (see chapter 1C) allowed 120 ml to flow into the bladder. The true bladder wall length was 8-9 cm minus urethral length of 1 cm. On this basis, it was felt that the small bladder capacity was not the main cause of the incontinence so a stress procedure with plication of the fascia under urethra was undertaken. After this procedure, a dye test (100 ml injected rapidly) was performed which showed a small leak at the site of the previous repair. This was repaired and a layer of pubococcygeal muscle was placed over the repair.

*Lesson:* Repeated examination is necessary to make a diagnosis. The gravity dye test is useful for measuring the bladder capacity.

**PERSISTENT FISTULA AFTER REPAIR**

- (a) *VVF:* A catheter can be re-inserted if the defect is discovered within 3 weeks of the initial operation. If conservative management fails, the next attempt at repair should preferably be after 2 to 3 months so that the tissues are less friable.
- (b) *Ureteric:* There is urine in the vagina but the dye test is negative.
  - It is possible for a VVF to heal (dye test negative) but for a ureter which was in the edge of the fistula to retract outwards and present as a ureteric fistula (see Fig 9.8).
  - More commonly a ureteric fistula may have been present before the VVF repair, but only becomes obvious when there is continued urine leakage after the VVF is closed successfully and the dye test is negative. The VVF usually occurs from the obstructed labour and the ureteric fistula is iatrogenic i.e. usually Caesarean section performed to treat the obstructed labour.

**STUDIES PERFORMED IN POST-REPAIR INCONTINENCE**

In one study where urodynamic studies were done in 149 patients who had an obstetric fistula repaired but had ongoing urinary symptoms (not just incontinence), the following were demonstrated:

Stress only: 49%	No stress or no detrusor over-activity: 5%
Stress and detrusor over-activity: 43%	In addition, 7% had post-void residual volumes of 150 ml or more.
Detrusor over-activity only: 3%	

Therefore over 90 % of women had urodynamic stress incontinence and 46 % had detrusor over activity.

*Reference: Urinary symptoms and urodynamics following obstetric genitourinary fistula repair: Goh JTW, Krause H, Tessema AB, Abraha G. International Urogynecology Journal and Pelvic Floor Dysfunction Volume 24, Issue 6, June 2013, Pages 947-951.*

In another study of 22 patients with post-repair incontinence urodynamic studies showed:

Stress incontinence with normal bladder compliance 41%	Stress incontinence with detrusor instability 41%
Stress incontinence with low bladder compliance 14%	Overflow incontinence 4%

*Reference: Stress urinary incontinence after delayed primary closure of genitourinary fistula: A technique for surgical management. Carey MP et al. Am J Obstet Gynecol 2002 May; 186 (5): 948-53.*

Therefore while stress incontinence is the major factor in post-repair incontinence, urgency is often present as well. It may be worth treating for urgency for a minimum of one month if medications are available and symptoms are persistent.

**(6.2) CONSERVATIVE TREATMENT OF POST-REPAIR INCONTINENCE**

Getting the patient to drink plenty helps to increase bladder capacity and should be part of conservative treatment. Also, encourage her to urinate frequently during the day.

**(1) STRESS INCONTINENCE**

No surgical treatment should be considered for 3-6 months after fistula repair because:

- Many cases improve with time especially if the fistula was non-circumferential.
- There is a risk that you may re-open the fistula if you operate, or create a new fistula in a difficult site.

However, surgery may be performed earlier in some cases if it is not convenient to wait six months provided that tension slings are not applied.

**(2) URGENCY URINARY INCONTINENCE**

While there is a lot of evidence for treating urgency incontinence in general, no one has ever done a study in fistula patients. Frequency is a big problem in fistula patients and it does not seem to improve with time.

- (a) Drugs: Anti-cholinergics e.g. Oxybutynin 5 mg 3 times daily can be used

- (b) for a month. Then reduce to 5 mg at night-time for 3 months. Tolterodine 2 mg twice daily or mirabegron 25-50mg/day are other options. Amitriptyline 50-75 mg at night-time is another more widely available but less satisfactory option. Be sure the post-void residual is normal before starting anti-cholinergics and do not use in the elderly or those with constipation.
- (c) Pelvic floor exercises: may be more useful in urgency than stress incontinence.
- (d) Timed voiding (bladder training).
- (e) Encourage the patient to drink plenty which may improve bladder capacity.
- (f) Surgery: Augmentation of the bladder if very reduced capacity (see section 10.2).
- (g) Bladder Botox and neuromodulation are other possible options.

There are two main types of abnormal bladder function:

- (a) *The over-active bladder*: In this case, the bladder undergoes increases of pressure as the bladder contracts during filling but then the pressure returns to normal in between contractions. The patient feels urgency symptoms. These patients often leak around their catheters in the early post-operative days.
- (b) *The non-compliant bladder*: i.e. the bladder cannot stretch. This is usually due to loss of elasticity or size. There may be a thickened bladder wall.
  - It is more common with neurogenic bladder, those with long-term obstruction and post-radiation. It is likely that many obstetric fistula patients with small bladders would be non-compliant.
  - During bladder filling, the pressure gradually increases all the time and does not fall. As bladder pressure will always affect the kidneys, if the pressure increases without any leaking via the urethra, then hydronephrosis occurs. The kidneys only tolerate pressures up to 20 cm H<sub>2</sub>O.
  - These patients are more likely to have impaired sensation and just leak small amounts all the time, often increased with activity.
  - Patients with a non-compliant bladder are more likely to develop high pressures if you place an obstructive sling.

### (3) MIXED STRESS AND URGENCY INCONTINENCE

- The traditional teaching in non-fistula patients has been to treat the urgency incontinence first and then the stress. This is because too many voiding disorders occur if you do a stress operation on patients with urgency incontinence. The patient can be treated with anti-cholinergics first and encouraged to drink plenty. Then if the urgency symptoms improve, an operation for stress can be considered.
- However, the experience in fistula patients has been that the outcome after a stress operation for patients with mixed incontinence is the same as for those with pure stress.
- The disadvantage of surgery is that you may increase the bladder pressure by creating an obstruction to the bladder neck with a sling procedure. However, in most cases, if a sling is placed in a patient with a smallish bladder it will result in frequency and not high pressures. After a sling is placed, it is unlikely that the bladder pressures will have increased if the patient:
  - Is not in retention and the residuals are < 100 mls.
  - Has a normal flow i.e. the patient does not have a weak flow or has to lean forward to micturate.
  - Shows no evidence of hydronephrosis or change in creatinine levels after 6 months.

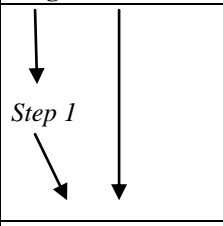

If there is evidence of increased pressure or if the patient has to pass urine frequently (e.g. every 30 minutes) then it would be a good idea to do an augmentation of the bladder.

### (6.3) SURGERY FOR STRESS INCONTINENCE: GENERAL

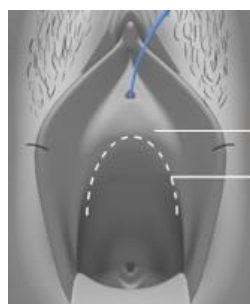
- If stress incontinence persists, consider surgery. There is little evidence to support the different treatments used for post-repair incontinence as long-term follow up of these patients is difficult. Therefore, most of what we do is based on experience. The problem with any surgery for stress incontinence is that initial results are often good but with time the incontinence often recurs.
- The factors that affect the function of the urethra as a sphincter are:
  - (a) *Length*: usually a urethra of 1.5 cm is needed for continence although some patients may be continent with a length of 1 cm. The continence mechanism is along the entire length of the urethra.
  - (b) *Width*: the narrower the urethra, the greater the resistance it can produce. In cases of stress incontinence, the urethra becomes wider with funnelling of the proximal urethra.
  - (c) *Support*: The aim of most operations is to support the posterior urethra and bring it closer to the anterior urethra and the pubic bone.
- The normal function of the urethral support system requires the contraction of the levator ani muscle, which supports the urethra through the endopelvic fascia. With an increase in intra-abdominal pressure, there is a reflex increase in the tone of the smooth muscle of the pubo-cervical fascia, which pushes the posterior urethral wall upwards and forwards towards the anterior wall. There is also an increase in the tone of the internal and external sphincters. All these increased forces occur just milliseconds before there is any increase in the intra-vesical pressure.

Reference: Waaldijk K. In "Obstetric trauma surgery art and science: functional pelvis anatomy in the female".

- Repair of fascial defects with re-fixation to the pubic bone will lengthen and narrow the urethra, and improve its support.

Initial transverse vaginal incision:	SUMMARY OF THE STEPS COMMONLY USED IN SURGICAL MANAGEMENT OF STRESS INCONTINENCE:
	<p><b>Step 1:</b> To narrow, lengthen and support the urethra, plicate the pubo-cervical fascia (pelvic diaphragm) under the urethra. This layer is then re-attached to the periosteum of the pubic bone on either side of the urethra. It is important to look for defects within the pelvic diaphragm and/or its attachment to the pubis bones and then repair them meticulously. Do not look just for fascia but also for smooth muscle since that is the main component of this layer. In some cases, there is not sufficient fascia to work with or it is completely fixed and immobile so you will have to skip to Step 2.</p>
<p>Step 2</p>	<p><b>Step 2:</b> Add a fascial sling using the fascia of one of the following: the rectus sheath, fascia lata or the fascia of a Singapore flap which is a combination of steps 2+3.</p>
<p>Step 3</p>	<p><b>Step 3:</b> If when you make the vaginal incision, the urethral opening springs forward or the cervix goes back or if there is any tension when you are closing the vagina, this would indicate a stiff anterior vagina with loss of normal elasticity. In these cases, consider a skin flap to avoid any tension in vaginal closure so there is no pull on the urethral opening.</p>
	<p>Intra-operative assessment of the effectiveness of the procedures is not very reliable. However:</p> <ul style="list-style-type: none"> <li>• If the patient appears to be wet at the end of the procedure, it is likely that she will be wet later.</li> <li>• If she appears to be dry when you get her to cough or press supra-pubically, there is a good chance that she will be dry post-operatively.</li> </ul>

**Incision:** Two common incisions are used which are quite similar. My preference is for the transverse incision as I find this gives better exposure of the distal tissues although a mix of the two incisions is also good.



apex of incision  
incision

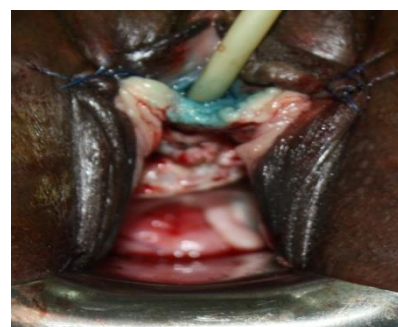
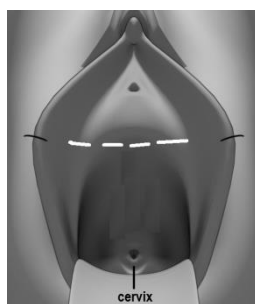


Fig.6.1b: Shows the inverted U incision. The apex of the incision should be approximately 2 cm proximal to the urethral meatus.

Fig 6.1c: Shows the transverse incision and Fig. 6.1d shows the same incision with the flaps now mobilized and the distal flap sutured back for exposure. Note that a dye test has been done before making the incision to exclude any small fistula.

- (a) **An inverted U incision:** (Fig 6.1b) is used to open the anterior vagina with the apex about 1.5 to 2 cm below the external urethral meatus. The anterior vaginal wall is dissected from the underlying pubo-cervical fascia and bladder to form a flap of vaginal skin. The incision is from ischial spine to ischial spine.
- Before you make the incision, place one Allis forceps just below or on the edge of the urethral opening and a second one, 1-3 cm lower.
  - Once the incision is made, move the two Allis forceps onto the edge of the incision i.e. to either side of the incision at the apex.
  - When dissecting the vagina off the bladder, stay close to the vagina. This avoids injuring the bladder and conserves more fascial tissue for plication.
  - To mobilize the distal flap, it is useful to use the curved Thorek scissors.
- (b) **Transverse incision:** is made 2 cm below the external urethral orifice. The incision is made wide enough to expose the urethra fully and to be able to feel the pubic bone laterally. The distal flap is mobilized and stitched back (Fig. 6.1d). Then the proximal flap is dissected. The advantage of this incision is that it gives better exposure distally than the inverted U incision.

**(6.4) SURGERY FOR STRESS INCONTINENCE: REPAIRING DEFECTS IN ± REATTACHMENT OF THE ENDOPELVIC (PUBOCERVICAL) FASCIA**

There are two ways of tightening the fascia and re-attaching it to the periosteum:

- (a) Most commonly you have to mobilize the fascia on both sides so that you can pull it across the midline under the urethra i.e. the defect in the fascia is in the midline and longitudinal so the fascia is first plicated across the midline. This is similar to an anterior colporrhaphy but more lateral dissection may be performed. See Fig. 6.3b, Fig. 6.4a.
- (b) In some cases, especially when the fistula was small or distal, the defect is more transverse with detachment of the fascia from the pubic bone. The fascia is found between the vagina and the bladder under the proximal vaginal flap. In these cases, the fascia is sutured directly to the periosteum without plication. See Fig. 6.4b and photograph in Fig. 3.1d.

The procedure can be performed at the time of the fistula repair to avoid stress incontinence in high-risk cases, or later as a separate procedure to treat stress incontinence. When performed later, there is an increased risk of urethral and bladder injury. The following are the steps of the procedure when it is done later. First, exclude any small VVF that you may have missed. Repeat a dye test as in Fig. 6.1a.

#### Dissecting out the fascia

- Pull the urethra/ bladder with the overlying fascia medially as you dissect laterally. Put Allis forceps on the fascia and pull medially as you dissect the fascia from the vaginal skin or bone out laterally.
- Start just below (proximal) and lateral to the urethral orifice. Stay close to the bone as you do this. A good tip is to start as distal and lateral as possible to avoid the bladder and urethra.
- If you open the para-vesical space (Fig. 6.2), this is recognized by seeing fatty tissue and the levator muscles laterally. However, it is better not to deliberately open this space as this will detach the fascia from the bone.

**Repairing the defects in the endopelvic fascia:** There are three common defects:

- (1) *Midline defect:* In over 90% of post-fistula repair incontinence, there is a median defect in the fascia. This can be checked for by pulling on the anterior vaginal wall before any dissection and see how mobile it is. Normally it is only slightly mobile whereas when there is a defect, it is more mobile. The defect is closed with interrupted sutures. Use 2/0 or 3/0 Vicryl or preferably PDS. Insert the most distal or proximal sutures first – it does not matter which you start with although I find it easier to start distally first. With the proximal suture, also take a bite of the cervix in the midline as the cervix is the focal point for fixation of the pubo-cervical fascia (Fig. 6.3a).

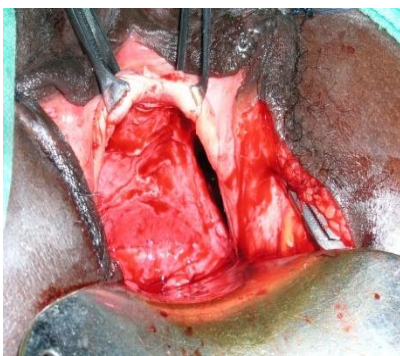


Fig. 6.2: Shows the para-vesical space open on the left. (K. Waaldijk)

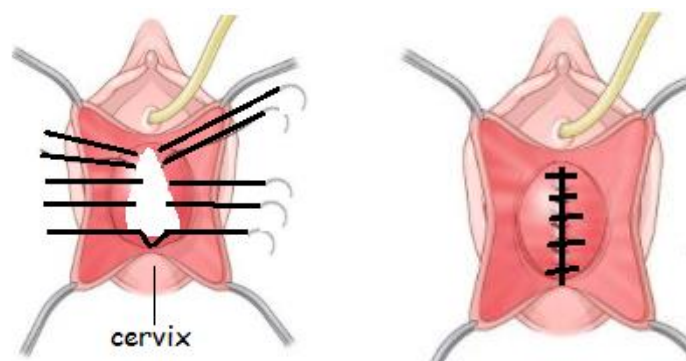


Fig. 6.3a: Shows the median defect in the pubo-cervical fascia being repaired.

- (2) *Distal transverse defect:* This may occur with midline defects or separately when it is seen in distal fistulas or urethral trauma. Therefore in some cases, the fascia does not need to be plicated longitudinally but only re-attached to the periosteum (Fig. 6.4b) i.e. on either side to the posterior aspect of the pubic bone (where the arcus tendineus is situated). It is fixed 2 cm from the midline where the arcus tendineus fascia is supposed to be and then more medially to the pubis bone periosteum.

Where the distal fascia is detached from the bone, the urethral orifice is often open widely (patulous urethra as in Fig. 6.3b) and you can often see into the bladder i.e. may even see the balloon of the Foley catheter. Re-attaching the fascia to the bone closes this defect to give the urethral orifice a normal appearance.

- Use PDS No. 1 suture or Vicryl if that is not available. Nylon sutures are best avoided as they often protrude out the vagina and will lead to stone formation.

- First, make small deep transverse para-urethral incisions on either side over the periosteum to improve the chance of the fascia staying attached.
- Two sutures on either side (para-urethral) are passed from the pubic arch at 10 + 11 and 1 + 2 o'clock positions to the fascia (see Fig. 6.4 a + b). This is performed directly from the pubic bone to the fascia without going through the vaginal wall.

(3) **Lateral defects:** In any circumferential fistula, there are antero-lateral fixation defects with the para-vesical spaces open (See Fig. 6.2) so the fascia needs to be re-attached to the bone with two sutures on either side.

**! Tip!** The endopelvic fascia has to be connected circumferentially to the pelvic bone for it to function properly. In genuine stress incontinence, there is no need to re-fix the fascia to the bone.

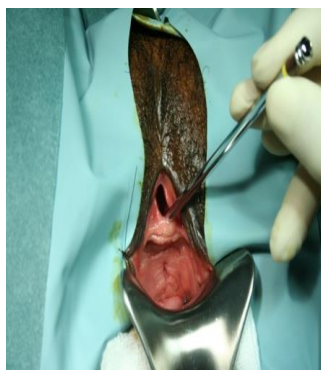


Fig. 6.3b: Shows a patulous urethra.

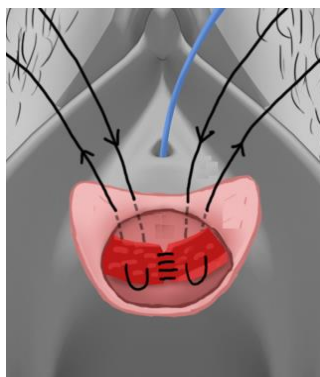


Fig. 6.4a: Shows the sutures going from the bone/ arcus tendineus to the fascia.

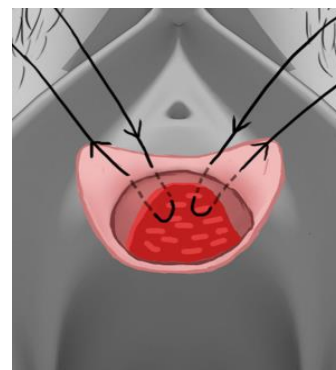



Fig. 6.4b: Shows the fascia being re-fixed to the periosteum without plication.



Flow chart for managing fascial defects in cases of post-repair incontinence.

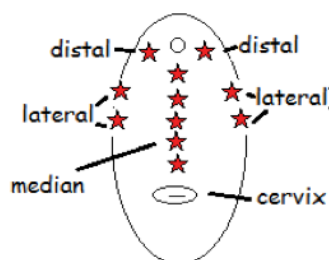


Fig. 6.4c: Summarises the position of the sutures inserted to correct the various fascial defects.

- When taking bites of the pubo-cervical fascia, if you go too deep there is a risk to the ureters.
- With any deep sutures to re-attach the fascia to the bone, avoid being too close to the urethra as this can result in partial necrosis of the urethra.
- Any defect within the endopelvic fascia (diaphragm) and its circumferential fixation has to be repaired.

**! Tip!** In genuine stress incontinence, there are median defects in the fascia without tissue loss whereas in post-repair incontinence, there are median defects with tissue loss.



**(6.5) SURGERY FOR STRESS INCONTINENCE: FASCIAL SLINGS**

This uses a free graft of the rectus fascia or the fascia lata of the thigh which is then fixed to the rectus fascia on one side, passed retro-pubically to run under the urethra as a sling and is then passed retro-pubically and fixed to the rectus fascia on the other side (see Fig. 6.6a + b for overview). Another more recent option is to use the fascia of a Singapore flap as a sling (see below).



- The fistula must be healed for at least four months before you can do a sling operation.
- Avoid the temptation to operate before four months just because the patient lives a long distance away and may have difficulty coming back. You will only make her worse.
- The urethra is a fragile structure which may necrose with tension.

**Position:** The patient is placed in the standard lithotomy position (as for fistula repair) with the buttocks well over the edge of the table. You need access to the vagina and the lower abdomen, so prepare a wide sterile area. Usually, the sling is performed after plication and fixation of the pubo-cervical fascia (section 6.3) although in some cases the sling will be performed without any repair of the pubo-cervical fascia if it is largely absent.

**(Step 1) VAGINAL DISSECTION**

- Exclude any small VVF with a dye test.
- Pass a Foley catheter and inflate the balloon with 3-5 ml. By pulling on the catheter, feel the position of the balloon which indicates the position of the bladder neck and where your initial incision should be. This is where the sling should sit.
- Make a transverse or inverted U incision and dissect laterally as described in section 6.3. Form a tunnel on each side for the sling to pass. As there is often scarring, dissect with scissors. Initially, aim laterally in the direction of the patient's shoulder on the side you are dissecting (see Fig. 6.4d) until you can get a fingertip into the area. Then with the scissors held vertically and the handle down (parallel to the perineum), aim 2-3 cm from the midline and keep the tips of the scissors close to the pubic bone at all times. Removing the vaginal speculum often helps when doing this step. When you have dissected sufficiently, a finger in the vagina should be able to touch a finger pressing down supra-pubically. This will later enable you to guide the Stamey needle down from the suprapubic region more safely by keeping it close to your finger passed up the vagina.

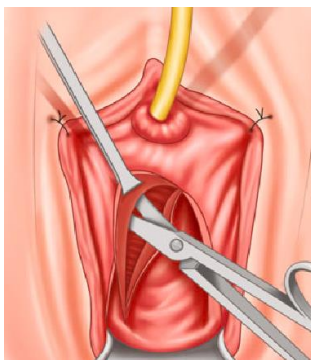


Fig. 6.4d: Shows curved scissors being passed under the pubic bone aiming towards the right shoulder.

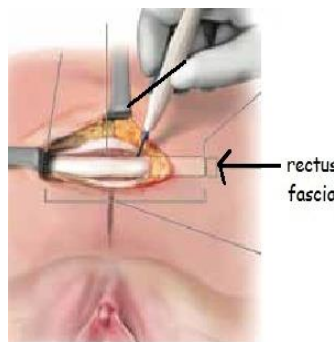
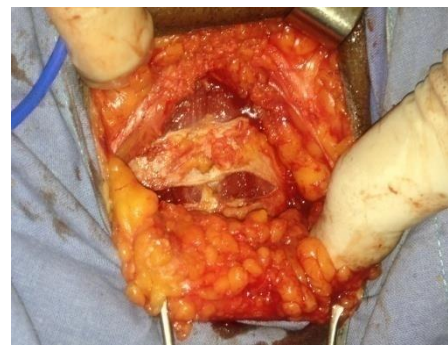

Fig. 6.5a + b: Shows a piece of rectus being cut out for the sling.

**(Step 2) ABDOMINAL DISSECTION**

Make a 5-6 cm in length transverse incision approximately 2-3 cm supra-pubically. Once you reach the rectus sheath, mobilize the fat off the sheath upwards for about 3 cm, then cut a 2 x 5 cm wide strip from the sheath (Fig. 6.5 a+b). Once the strip of sheath is free, pass a Prolene No. 2 suture into each end taking two bites of the sheath (Fig. 6.5c). Do not tie the suture, but leave the ends about 8 cm long on an artery clip.



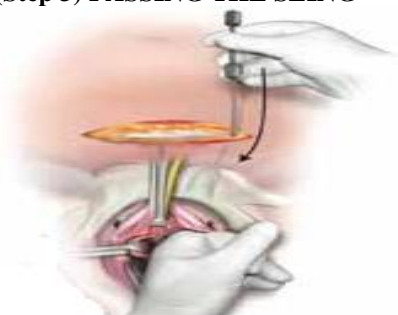Fig. 6.5c: Prolene stitch is attached to each end and a marker stitch is placed in the middle.



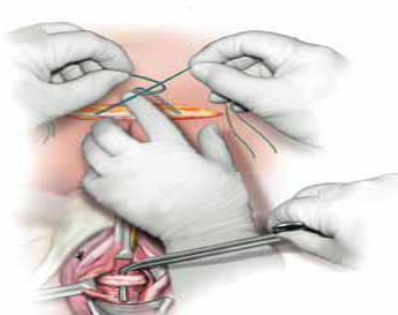
Fig. 6.5d: Shows a Stamey needle used to pass the sling.

**! Tip!** Place a stay stitch in the centre of the sling (as in Fig. 6.5c) so that you can see later that the sling is centered over the urethra. You can use any suture material to do this.

**(Step 3) PASSING THE SLING**



*Fig. 6.6a: The Stamey needle is being passed from above the pubic symphysis into the vagina to retrieve the Prolene ends.*



*Fig. 6.6b: Shows the ends of the Prolene suture being tied across the midline abdominally. Vaginally it shows a forceps being placed between the sling and the urethra so that the sling is not too tight. However, in post-VVF cases, this is **not** done as it would not give adequate support.*

- Make sure the bladder is empty and leave the catheter in situ. You may perform another dye test before placing the sling if there is any concern from your dissection. Small iatrogenic fistulas after dissection are not rare.
- With the sheath still open, a Stamey needle (Fig. 6.5d) is passed from just above the pubic bone in line with the pubic tubercle. To avoid injury to the bladder, stay close to the back of the symphysis. The rule is to stay close to the bone but do not scrape it. Move slowly and if it gets stuck, you usually need to change the angle. A Stamey needle will cause minimal trauma to the bladder if there is accidental perforation.
- With your left hand in the vagina (Fig. 6.6a), the Stamey needle should come in direct contact with your left index finger. Guide the needle first into the para-urethral space and then into the vagina.
- Now attach the two ends of the Prolene on one side (with the sheath attached) into the Stamey needle. Pull the needle back up.
- The same procedure is repeated on the other side.

**! Tip!** One way of checking if the Stamey needle has accidentally entered into the bladder if cystoscopy is not available is to use the metal-to-metal test. Pass a metal catheter via the urethra to see if you can feel the Stamey needle in the bladder. Also, the dye test may alert you later, showing leaking suprapubically or vaginally.

**! Tip!** If a Stamey needle is not available, long artery forceps can be inserted suprapubically to retrieve the Prolene sutures from the vagina. The disadvantage of artery forceps is that if the bladder is entered, the opening will be larger and is less likely to heal spontaneously.

**! Tip!** If a midline abdominal incision has been made for another reason, to harvest the sling you can cut a strip of fascia on one side longitudinally from the edge of the incision.

*Adjusting the tension on the sling:* How tightly you tie the sutures determines the tension on the sling. There are two options:

- The sling is inserted free from tension. Have a catheter (16F) in place throughout the operation. However, it is not possible to ensure that there is absolutely no tension on a sling. Even if one could do that in one position (i.e. on the operation table) it would not be possible to say the same applies when the patient gets up. The best you can do is to ensure there is some support, without obstructing. If a sling is inserted at the time of urethral reconstruction or fistula repair, it should definitely be inserted this way.
- The sling is inserted with tension so that you deliberately try to obstruct. In many fistula patients, if you do not pull the sling tight enough, it will not correct incontinence. However, if there is too much tension, it will result in erosion of the tissues or urinary retention.

**(Step 4) FIXING THE SLING:** use either of two methods:

**(A) Fix each side separately:**

- Site: Suprapubically to the lower flap of the rectus sheath about 2-3 cm from the midline on each side.

- Fix the two ends of Prolene to the rectus sheath using a free needle. Pass the ends of the Prolene from inside to outside on the rectus sheath approximately 1cm apart.
  - Then fix the other side in the same way.
  - Close the sheath incision before you tie the sling sutures, otherwise the sling tension tends to pull the sheath down, which makes closure more difficult. Ensure that the sutures used to close the rectus sheath are not too close to the sling sutures as they may interfere with tying of the sling sutures. Alternatively, it is safer to close the sheath with interrupted sutures to avoid interference with the sling sutures.
  - On the right side, tie the two ends of the Prolene together and leave the ends long.
  - It is easier to adjust the tension properly as you tie the left side with the right side already fixed.
  - Check vaginally that the centre of the sling (marked with stay stitch *Fig. 6.5c*) is over the urethra.
- Last step:* After the Prolene sutures are fixed on each side to the rectus sheath and the tension adjusted, it is a good idea to tie the ends on one side across the midline to the ends of the other side as an extra security.

**(B) Tie both sides together:** After passing the sutures through the sheath, instead of fixing the sutures to the rectus sheath, you can tie the two sides across the midline as in *Fig. 6.6b*. Fill the bladder with 100 ml and get the patient to cough. The tension is adjusted so that there is no leakage when the patient coughs. However, if you have already plicated the pubo-cervical fascia, the patient is often already dry by this stage. There is probably a greater risk of obstruction and retention if this method is used.

**(Step 5) AFTER FIXING THE SLING:** Fill the bladder with 100 ml of dye. This allows you to see:

- If you have injured the bladder you will see dye coming out vaginally or supra-pubically but not through the urethra. If this happens, remove the sling and try again. It is usually only the needle (and the Prolene suture) that has perforated the bladder, so the opening should be small. A Foley catheter should be left in for two weeks if you have perforated the bladder.
- If the bladder can now hold this amount of fluid it indicates the operation is likely to be successful.
- Do a cough test: after doing the dye test, remove the Foley (measure the new urethral length) and get the patient to cough. If she has been sedated, push supra-pubically instead. As mentioned above, the patient can appear dry in the operating room but may still have incontinence later.

*Other options:*

There are some additional manoeuvres that can be of use if doing a sling after previous VVF repair but these are not routine:

- (a) Open the retropubic space more rather than passing Stamey needle blindly. If bleeding occurs, it can be controlled by upward compression. The surgeon's fingers in the vagina are applied against a sponge forceps pressed down from above. This compresses the veins and then they can be cauterised.
- (b) Do a deliberate cystotomy or cystoscopy to check that you have not injured the bladder.

### FASCIA LATA SLING

If it is not possible to get a good strip of fascia from the rectus due to previous surgery or deficient fascia, then this is a good alternative. In fact, because the fascia is stronger here, many surgeons prefer using this fascia rather than the rectus sheath. It also avoids the risk of abdominal wall hernia. However, for post-fistula patients, you cannot be sure if you will proceed with a sling (e.g. bladder opened during dissection) so it is often more convenient to use the rectus fascia.

- Put the patient on her side with a pillow between her thighs, or adjust the lithotomy position so that you can access the lateral thigh.
- Make a 4 cm longitudinal (easier) or transverse (more cosmetic) incision in the lateral thigh approximately 3-5 cm above the lateral femoral condyle. The reason for making the incision low is that there is usually less fat to cut through, the closer the incision is to the knee.
- Using two small Langenbeck retractors placed in the centre of the incision, stretch the incision to expose the fascia.
- With a knife, make two parallel longitudinal incisions of 4 -5 cm length and 2 cm width in the fascia. Then using scissors, cut the upper end of this strip of fascia transversely and mobilize the fascia down to the lower end which is now cut transversely.
- Do not close the defect in the fascia lata, as this creates tension and pain. Muscle will not herniate. Close the thigh skin with absorbable suture.
- You will now have to make a 3-4 cm transverse suprapubic incision in the skin to fix the sling.

**SINGAPORE FLAP AS A SLING:** (see also chapter 8). It is possible to use the fascia of this flap as a sling especially if the fascia is of good quality. I usually do the fixation of the suture to the rectus on one side only i.e. on the opposite side from where it is harvested although you can do it bilaterally. Using Nylon or Prolene suture (take a figure of 8 bite of the fascia), the fascia is attached to the rectus sheath. In this case, the fascia is still

attached to its blood supply. The long-term effectiveness has not been studied. I would only use it if I was placing a Singapore flap for vaginal closure.

### MODIFIED SLINGS FOR POST-FISTULA CASES

These variations are or have been used to improve the success rate of slings or reduce complications. The first option is the only one that I use regularly.

**(1) To reduce the risk of erosion:** Because the amount of tension applied to the sling has to be greater or the tissues are weaker, there is a significant risk of erosion by the sling into the bladder and/or urethra resulting in the formation of a new fistula. To reduce this risk, one of the following modifications should be added:

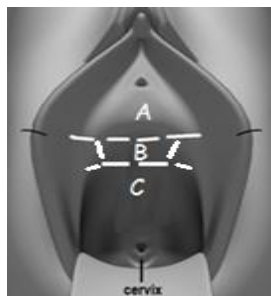


Fig. 6.7a: Shows an area of vaginal skin (B) which is left intact

- Place a Martius flap under the sling in the midline or
- Leave an area of the vaginal skin attached to the urethra/ bladder (Fig. 6.7a). After making the usual transverse incision, make another one 2 cm below it. Then make two incisions laterally so that area B is formed (Fig. 6.7a). The sling is then placed over area B and attached with a few sutures so that it stays apposed to this area. This intact vaginal skin acts as a buffer between the sling and the bladder. The potential problems are:

- (a) It can be difficult to know exactly where to leave the skin island intact so that the sling will sit on it. Pull on the Foley catheter and feel the balloon, which will indicate the site of the bladder neck. The sling should sit just distal to this site.
- (b) There is a risk of seroma when the vaginal skin is buried. To avoid this, cauterize the skin of area B (to be buried) with diathermy very superficially to a depth of 1 mm to prevent the formation of any secretions by the skin.

The incision is then closed over to bury the sling. For closure of the vagina, either: (i) undermine the vaginal skin distally (A in Fig. 6.7a) and proximally (C) and oppose it to bury the skin and the sling. (ii) As there is often insufficient skin in these cases, a Singapore flap may be required for closure.

### (2) To reduce the risk of complications: Mini-sling

In this operation, instead of fixing the rectus sheath suprapubically, it is stitched directly to the pubic bone on either side of the urethra at 10-11 o'clock and 1-2 o'clock positions with PDS No. 2 suture (on right in Fig. 6.7b). Avoid using non-absorbable suture as it often protrudes out through the vaginal skin and can lead to stone and granulation formation.

- It would be mainly indicated in those cases where there is dense scarring or little mobility of the tissues so that you do not want to do much dissection.
- The main problem with this sling is that the amount of tension that can be generated is limited so it is often not effective. Make sure the sling is in apposition to the urethra rather than tented across the urethra. To achieve some tension, if the sling is too long, the bites are taken (see Fig. 6.7b) on the left side along the sheath rather than at the end of the sheath. After placing the suture, verify that the tension is tight enough with testing via cough or suprapubic pressure. If she is still leaking, you can place an additional stitch to tighten the sling further.
- If there is excess fascia left over, this can either be excised or double backed over the main fascia to provide extra bulk.
- The risk of injury to the bladder or erosion to the urethra should be very low.

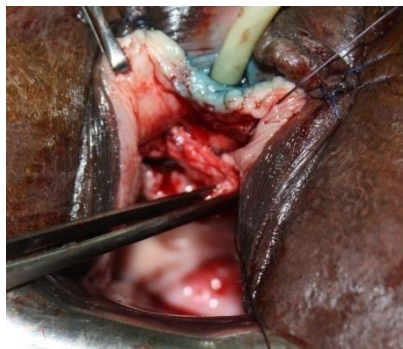


Fig. 6.7b: Shows a mini-sling procedure. The rectus sheath has been stitched on the right side to the pubic arch at 11 o'clock and is about to be fixed at 1 o'clock.

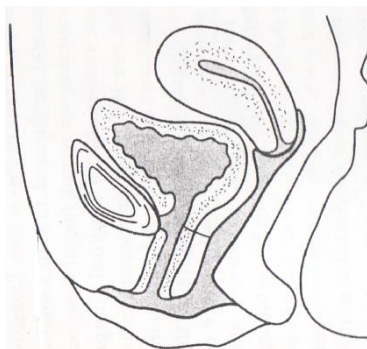


Fig. 6.8: Shows a case where the fistula has been closed but the anterior urethral wall remains continuous with the pubic symphysis.

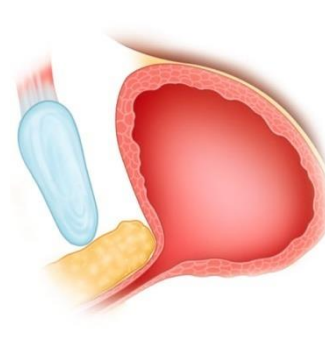


Fig. 6.9: Shows a Martius graft in yellow inserted between the urethra and the pubic symphysis. The procedure is performed via a supra-meatal incision.

**(3) To increase the effectiveness of the sling: Mobilizing the urethra**

Pubo-vaginal slings normally work by dynamic compression (such movement is usually rotational) and therefore need a mobile urethra. In fistula patients, the anterior urethra is often fixed to the back of the pubic symphysis, especially after a circumferential repair (see Fig. 6.8). Therefore, some have tried to mobilize the urethra first before performing a sling. To mobilize the urethra, either one of the following procedures can be performed:

- Retropubic dissection is performed to mobilize the urethra and an omental graft is placed in the retropubic space to reduce the risk of re-adherence of the urethra to the pubic symphysis. This is then followed by placement of the sling. In such circumferential cases, there is a high risk of making a cysto-urethrotomy although closing the defect, placing omentum or fascia, and leaving a catheter in for 10 days should lead to healing.
- A similar procedure can be attempted vaginally through a supra-meatal incision and using a Martius graft (see Fig. 6.9).

*Reference: Stress urinary incontinence after delayed primary closure of genitourinary fistula: A technique for surgical management. Carey MP et al. Am J Obstet Gynecol 2002 May; 186 (5): 948-53.* In this study, the sling was applied without tension and continence rates of around 68% were achieved at 14 months follow up. However, technically it is a difficult procedure and cannot be recommended at present.

- (4) Synthetic slings:** These are designed for those with urethral mobility i.e. the urethra descends to hit the mesh sling and then closes. If the urethra is not mobile, you need to bring the sling up to the urethra and provide some degree of compression e.g. fascial slings. It is not a good idea to place mesh in a scarred anterior vaginal wall that is not mobile. Mesh placed under tension may erode into the urethra with subsequent fistula formation. When first used in fistula patients, synthetic slings were quickly abandoned due to these problems. They could only be considered if placed over a layer which protects the urethra e.g. previous Martius flap or Singapore flap. However, even in this situation, it is difficult to make recommendations as the experience is limited.

**(6.6) URETHRAL STRICTURE**

**Urethral strictures due to non-obstetric trauma:** see section 4.5. This section should be read in conjunction with the following as many of the points overlap.

**Urethral strictures due to obstetric trauma:** Stricture of the urethra may occur at the meatus, along the length of a new urethra or at the junction with the bladder. These are seen occasionally after fistula repair especially if: (a) A circumferential VVF was not managed correctly. (b) A neo-urethra was created. (c) A fistula at the bladder neck was closed longitudinally instead of transversely.

*Diagnosis:* In many cases, the patient presents with continuous leaking but the residual volumes are not usually high. In these cases, there is over-activity of the bladder in response to the stricture. In some cases, there will be a high residual urine volume. Diagnosis is usually made by failure or difficulty to pass a metal catheter into the bladder. *Management:* Strictures are difficult to manage and whatever you do, they commonly recur as they do not epithelialize.

**OPTION 1: DILATION:** Milder cases may be suitable for this. (See section 2.3 *If the urethra is stenosed* for different ways of dilating.) Once through the stricture, you should then dilate up to 16 to 18 F. There is no need to dilate further. Remember when dilating the urethra, use plenty of lubricant gel and stay close to the bone to avoid perforating through the (posterior) urethral wall. Always do a dye test after dilation to exclude a fistula. There are two problems with dilation: (a) The stricture often recurs quickly. (b) It is easy to make a false passage especially in the more severe strictures. This can be recognised by doing a gravity dye test after dilating i.e. if the dye does not flow in or does not flow back out freely, then it is likely that the catheter is not in the bladder.

**CAUTION!** If you have used a dilator to open the stricture and you think the dilator has gone in too far, there may be a perforation. In this case, it is best to check supra-pubically or with cystoscopy or cystogram if available. An intra-peritoneal leak towards the dome of the bladder may not heal with just a catheter. In this case, the patient will develop gradual abdominal distension after the catheter is removed. An open repair is best. In contrast, extra-peritoneal leaks heal well with a catheter because they have fat etc around them.

*Longer term management:* Strictures nearly always recur. Therefore after dilating or surgical treatment:

- *If the patient is dry:* she should do intermittent catheterization at least once a week. Use a short stiff catheter which she holds in place for a few minutes.
- *If the patient is wet:* do a stress procedure but also get the patient to do intermittent catheterization once daily in order to keep the urethral lumen patent. Another option is to use a urethral plug if available.

Some believe that strictures will recur even with dilation and the benefit of dilation is that you will know when they recur, as the patient can no longer catheterize herself.

## OPTION 2: SURGICAL TREATMENT

If the stricture is completely solid and there is difficulty inserting a small dilator safely, then it is better to incise through the stricture. Via a transverse incision in the vagina, make a longitudinal incision through the stricture (Fig. 6.10a). Use a metal catheter, guide wire or dilator to locate the site of the stricture. Then cut down just proximal to this for a distance so that the dilator can pass easily. Remember that when trying to pass the dilator past the stricture site, the urethra normally curves posteriorly so make sure you are pushing in the correct direction, otherwise you may make the incision too long.

**!Tip!** Try to get a small dilator or guide wire through the stricture as this makes it much easier to see the lumen and length of the strictured area.

(A) **Incision and anastomosis:** Excise the stenotic area, mobilize and close transversely (Fig. 6.10a). However, this may not be so easy to do in practice as the female urethra is already short in length. There is still a risk of re-stenosis. Some believe that a buccal mucosa graft is a better option in all cases even if the stricture is only 1 cm in length.

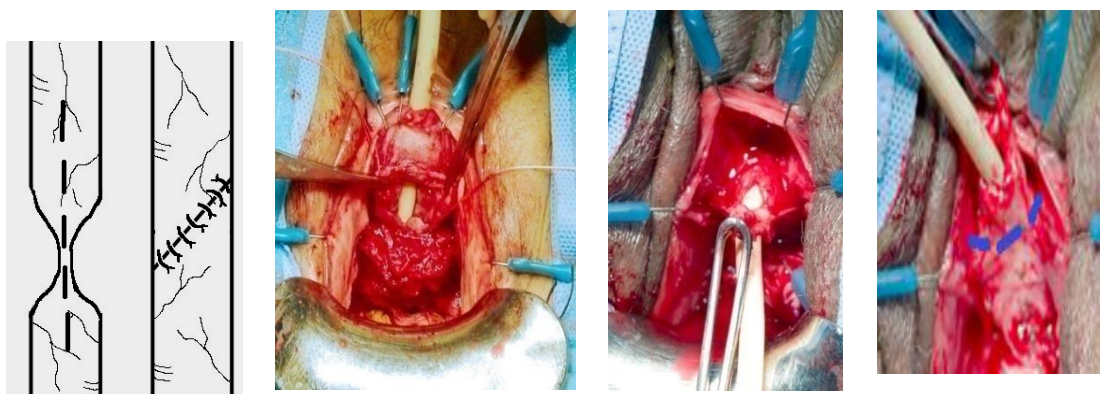


Fig 6.10a: A longitudinal incision is made through the stricture. The closure is done obliquely widening the stricture area. Oblique closure is less likely to re-stricture than transverse closure.

Fig. 6.10b: Shows a longitudinal incision made through the urethral wall for a proximal urethral stricture.

Fig. 6.10c: Shows a distal stricture after a suprameatal incision has been made. The distal anterior urethra is incised through the strictured area.

Fig. 6.10d: Shows the distal posterior urethral wall exposed, and a circular incision (in blue) will be performed to complete the excision of the distal urethra with the stricture (see section 4.5 page 74).

(B) **Buccal mucosa graft:** If the stricture is long and there is loss of tissue, another option is to use a buccal mucosa graft. This procedure may carry a risk of urinary incontinence post-operatively. An incision is made in either the anterior or posterior aspect of the urethra which is incised longitudinally to divide the stricture.

- Anterior (termed dorsal) approach is preferable as there is little risk of causing a fistula. A supra-meatal incision is made (see Fig. 4.12b) to expose the anterior aspect of the urethra. The urethra is freed up to the bladder neck (using the Foley catheter as your guide) and then opened anteriorly.
- Posterior (termed ventral) approach is made through the vagina (Fig. 6.12). This should be a more familiar approach.

**Method:** A buccal mucosa graft from the mouth is applied to fill the resulting defect. A length 4-6 cm and width 2-3 cm can be taken (see Fig. 6.11). However, you can make a smaller size graft i.e. even 1-1.5 cm length if necessary. The opening in the urethra/ bladder can be enlarged if necessary to fit the graft.

- Three stay sutures are placed through the lip in one corner of the mouth to provide traction. One at the angle of the mouth, one just below the angle and one above it (see Fig. 6.11a). If necessary, an assistant can retract by placing his thumbs inside the mouth. A self-retaining retractor is not essential.
- The endotracheal tube is turned to the left side if you are taking the graft from the right. If the patient is already under spinal anaesthesia then an induction dose of ketamine or another suitable general anaesthetic needs to be given. The increased salivation due to ketamine makes it easier to see Stensen's duct. Place a gauze swab between the lower teeth and the cheek to absorb any blood. Suction is needed too. Infiltrate with diluted adrenaline 1:200,000. Inject plenty all around with a small needle so there is less bleeding.
- First outline (with a superficial cut) the graft area by using a knife (Fig. 6.11) to cut through the mucosa. Go from deep inside the mouth towards the angle of the mouth separately on each side. Go 1 cm below Stensen's duct opening which is close to the last two molar (upper) teeth (Fig. 6.11b).

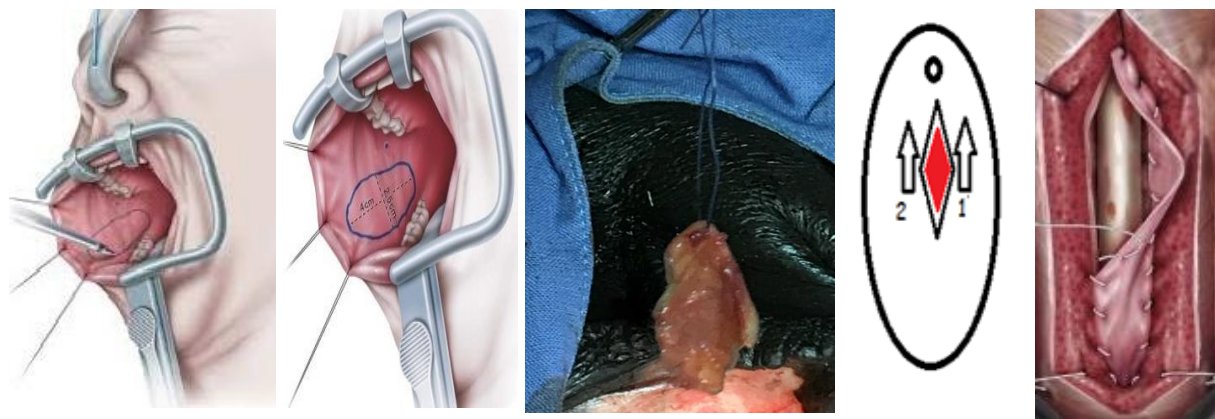


Fig. 6.11a: Shows the graft area being outlined with a scalpel.

Fig. 6.11b: Shows the dimensions of the graft. Note the position of Stensen's duct opening marked by a dot near the upper teeth.

Fig. 6.12: Shows a stay stitch on the apex of the graft (urethral meatus end) to help keep it in place as it is sutured in place.

Fig. 6.13: This is an example of a buccal graft applied on the posterior urethra with the catheter in place. The two arrows show the direction of the sutures.

**Tip!** To protect the parotid duct, initially make a small incision 1 cm inferior to the duct (which is part of the full incision) before any other cutting. This marks the safe limit very clearly at a time when there is no bleeding.

- To remove the graft work from out to in. Use scissors and dissecting forceps/ pickups to cut out the graft. You can see the underlying muscle as you cut out the mucosa but do not include this in the graft.

**Tip!** After you have dissected the outer part of the graft, place a stay stitch on it to lift it up as you mobilize it as this makes it easier to see the inner dissection which is more difficult.

- The donor site is closed with a continuous catgut or Vicryl suture.
- The graft is prepared by removing any excess fat and muscle, using scissors to do this. The graft is stretched out either with pins/ needles or wrapped over your index finger. There should be no muscle and only a little fat remaining on it. However, be careful not to cut through the graft as you do this.
- It is then kept in saline until ready to use.

**Applying the graft to the urethra:** The buccal mucosa graft is sutured to the margins of the opened urethra (see Fig. 6.12) with the mucosal side facing the lumen of the urethra.

- The bites on the graft side have to be close to the edge and the bites of the urethra have to mainly include the mucosa.
- It is best to do this with the Foley catheter in place. If the catheter is in the way while inserting the sutures, either you or your assistant pushes it medially with the tip of artery forceps or use fine dissecting forceps.
- To fix the graft in place (Fig. 6.12), two separate continuous sutures of a 4/0 or 5/0 PDS or Vicryl are started at the apex of the graft (red area) and run distally on each side. The initial bite is from out to in on the graft and then in to out on the urethra so the knot ends up on the outside.
- Before trimming any excess graft tissue as you reach the distal end, allow for 20% more tissue than you think you will need as there will be 20% shrinkage in the graft size with time.
- Get a layer of tissue such as a Singapore or Gracilis flap over the buccal mucosa as it relies on the surrounding tissues for its blood supply. A Gracilis is more reliable than a Singapore for blood supply.

**Post-operative:** Liquids are allowed anytime after surgery, soft diet Day 1 and regular diet Day 2.

**Case History:** A patient who had a VVF repair performed one year previously (no notes available) presented with urinary incontinence. On examination she was found to have a full bladder which failed to empty after voiding. There was a tight urethral stricture. At operation, a transverse incision was made in the vagina. A vertical incision was made through the stricture. A buccal mucosa graft was applied and sutured in place with 4/0 Vicryl as in Fig. 6.13. This was covered with the surrounding tissues as a second layer. A Singapore flap was placed over the repair. Her dye test on Day 18 was negative. She voided well after the catheter was removed with only mild stress incontinence.

**COMBINATION OF STRICTURE AND STRESS:** This is not uncommon and there are no hard rules about how to manage these cases. Either: (a) Dilate the stricture first and then see how much the patient improves before considering surgery for stress incontinence. (b) Treat both at the same session: this would apply especially for the more severe strictures.